

Comparative analysis of root canal length determination using cone-beam computerized tomography and apex locator

Aleksandra Đeri¹, Irena Radman Kuzmanović¹, Adriana Arbutina², Renata Josipović¹, Saša Marin³, Mirjana Umićević-Davidović²

¹University of Banja Luka, Faculty of Medicine, Department of Dental Diseases, Banja Luka, Republika Srpska;

²University of Banja Luka, Faculty of Medicine, Department of Orthodontics, Banja Luka, Republika Srpska;

³University of Banja Luka, Faculty of Medicine, Department of Oral Surgery, Banja Luka, Republika Srpska

SUMMARY

Introduction Determining the length of the root canal is one of the key factors that can affect the outcome of endodontic therapy. Incorrectly determined working length results in underfilled or overfilled canal.

The aim of this work was to verify the effectiveness of cone-beam computerized tomography (CBCT) and apex locators in determining working length of the root canal.

Material and method Endodontic procedure was performed according to established endodontic protocol on 98 teeth. Teeth were divided into two groups: single-rooted and multi-rooted teeth. In both groups, working length was measured with an apex locator (Woodpex III) and CBCT (Planmeca Viso). In multi-rooted teeth, the canals were classified according to their morphological position into the groups Lingvomesial (LM), Buccomesial (BM), Bucodistal (BD), Palatal (P) and Distal (D) canals. Root canal length was determined by a dentist using apex locator at the University of Banja Luka while CBCT analysis was performed by a radiology engineer at the 3DENT radiology center in Banja Luka.

Results CBCT odontometry had small deviations from apex locator odontometry. The mean value of the absolute difference between CBCT measurement and apex locator measurement was the smallest in the group of linguomesial canals (0.284 mm), and the largest in the group of distal canals of the lower molars (1.939 mm). Based on the results of the Mann-Whitney U test, it was concluded that there was no statistically significant difference ($p > 0.05$) in measured length of the root canal between the two methods in all groups of roots of multi-rooted teeth as well as in the group of single-rooted teeth.

Conclusion CBCT odontometry is as reliable as apex locator odontometry.

Keywords: root canal length; CBCT diagnostics in dentistry; odontometry

INTRODUCTION

Today's dental procedures inevitably involve the use of digital technologies. CBCT can be used for digitized determination of the length of the root canal. In CBCT odontometry, the patient is exposed to a minimal level of X-ray radiation while scanning the inside of the tooth root canal (endodontium). The CBCT device emits conical X-ray radiation while detectors collect information about the way X-rays pass through dental and surrounding structures. After scanning, collected data is used to reconstruct a three-dimensional image of dental structures [1, 2]. Image processing software allows endodontists to make precise measurements of the root canal length. However, due to exposure to X-ray radiation, the use of CBCT is performed with caution and in accordance with strictly controlled clinical indications, especially when endodontic protocol is carried out in children [3, 4, 5].

Decision to use CBCT in dental treatment is usually made based on the need for accurate diagnostic information and treatment planning. Although odontometric

devices, also known as apex locators, are useful in determining the exact length of the root during endodontic treatments, there are several potential disadvantages or challenges that can arise with their use [6].

Apex locators use electrical impedance or sound signals to determine the length of a root canal. However, various factors, such as the presence of fluid or bleeding in the canal, the presence of metal fillings or a curved root canal, can lead to inaccurate results. This can lead to suboptimal treatment, including over- or under-instrumentation and obturation [7, 8]. Correct use of the apex locator requires a skilled operator. Incorrect placement or use of the device can result in inaccurate measurements. Apex locators are not recommended in certain situations, such as the presence of metal crowns or if the patient has an implanted pacemaker, and the use of low-frequency current could disrupt the rhythm of pacemaker. Proximity of mandibular canal should also be taken into account during endodontic protocol on the lower posterior teeth, because inadequate odontometry can lead to injury to the mandibular canal if it is in the immediate vicinity of the

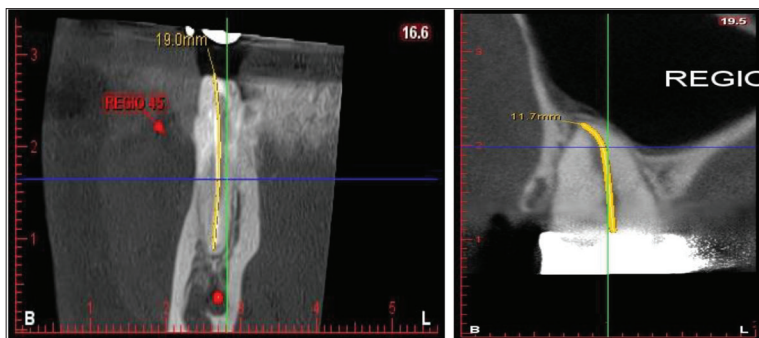


Figure 1. CBCT odontometry – Software compensation of the curved part of the canal

Slika 1. CBCT odontometrija – Softverska kompenzacija zakrivljenog dela kanala

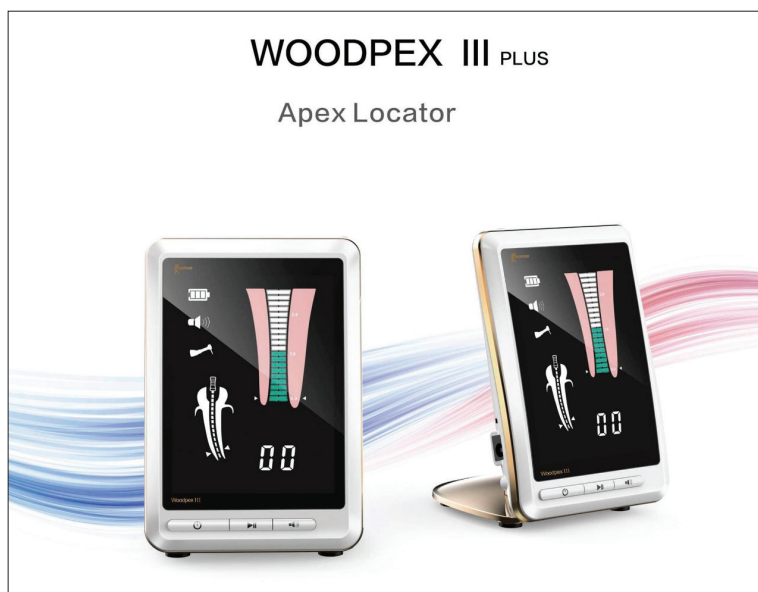


Figure 2. Apex locator

Slika 2. Apeksni lokator

apical foramen. In such cases, it is recommended to use CBCT odontometry as an alternative method [9–12].

Apex locators require maintenance and calibration to be accurate. Improper maintenance or malfunctions of the device can lead to inaccurate measurements. Quality apex locators can represent an investment for a dental practice. On the other hand, apex locators are usually not a source of ionizing radiation like X-ray machines, but use electrical signals or sound waves. Nevertheless, the issue of patient exposure to electromagnetic radiation remains a topic of concern and research. The above shows the need for a new, more modern method of odontometry [13, 14, 15].

The aim of this work was to verify the effectiveness of cone-beam computed tomography (CBCT) and apex locators in determining working length of the root canal.

MATERIAL AND METHODS

The research was carried out within the project of the Faculty of Medicine of the University of Banja Luka at the Department of Dental Medicine under the auspices of the Ministry of Science, Technological Development

and Information Systems of the Government of the Republika Srpska (project no. 19/6-020/961-48/18) as a retrospective study in the period 2019–2022. The study included 196 root canals of teeth that were indicated for endodontic treatment. Measurements of the length of the tooth root canal were performed on the complete sample – odontometry using the CBCT method (Planmeca ProMax 3D Classic (Planmeca, Finland) with a voxel size of 0.2 mm and a field of view of 4 × 4 cm) and determining the length of the root canal with the apex locator Woodpex III (Woodpecker Medical Instrument Co, Guilin, China).

There were six groups formed to measure root canal length:

1st group: Palatal canals of upper multi-rooted teeth – 24

2nd group: Buccomesial canals of upper and lower multi-rooted teeth – 49

3rd group: Bucodistal canals of upper multi-rooted teeth – 24

4th group: Linguomesial canals of lower multi-rooted teeth – 25

5th group: Distal canals of lower multi-rooted teeth – 25

6th group: Canals of single-rooted teeth of the upper and lower jaw – 49

1. CBCT odontometry

By analyzing the CBCT section, we first determined the position of the anatomical apical foramen, which represents the first reference point.

Then, linear measurements were made to another reference point (determined arbitrarily – incisal edge, cusp tip or curved surface) (Figure 1). Linear measurements were parallel to the vertical axis of the tooth and were made from one reference point to another, where the axial cross-section allowed drawing a straight line from the anatomical foramen to the tip of the cusp or the incisal edge of the tooth. The measurement was more reliable as it was performed on both the mesio-distal and vestibulo-oral sections, after which the mean value of the measurement was calculated and taken as the working length. In the case of curved canals, it was suggested to use segmented linear measurements that form a certain angle with each other. The disadvantage of this method of odontometric measurements is that the reference points for measurement are set according to the curved path of the canal, which can affect repeatability of measurements. 3D Endo-software (Planmeca Viso, Helsinki Finland) has an innovative feature to detect the semi-automatic path of the root canal, after scanning the entrance to the canal, thus minimizing the possibility of subjective operator error. The software also compensates for curved surfaces and unevenness or depressions in the interior giving more reliable measured size (Figure 2).

2. Odontometry with apex locator

Electronic determination of the working length using the apex locator is based on fact that resistance between the tip of endodontic instrument that is in contact with the periodontium and oral mucosa is approximately constant and amounts to 6.5 k Ω . Soft tissues are conductors of low-frequency alternating current and contact of the endodontic instrument with the periodontal tissue closes the current circuit, which is read on the display of the apex locator. At the moment when it is observed on the display that we are in the area of the apical foramen (first reference point), the rubber stopper is placed in the position that determines the second reference point. After that, endodontic instrument is removed from the canal and the distance between the first and second reference points is measured. The obtained value is the working length of the tooth root canal (Figure 3).

RESULTS

For multi-rooted teeth (molar region), measurements are shown individually for the buccomesial (BM), linguomesial (LM), palatal (P) and distal (D) canal (Tables 1–3). Based on the results of the Mann-Whitney U test, it was concluded that there was no statistically significant difference $p > 0.05$ in the measured length of the tooth root canal between the two methods in all groups of multi-rooted teeth.

Table 1. Odontometry measured with apex locator

Tabela 1. Odontometrija izmerena apeksnim lokatorom

Root Koren	N	Minimum Minimum	Maximum Maksimum	Average value Srednja vrednost	Standard deviation Standardna devijacija
BM	49	14.00	21.00	17.9184	1.81242
BD	24	16.00	22.00	18.2083	1.64129
P	24	18.00	24.00	20.9167	1.90917
D	25	16.00	24.00	20.4800	1.93907
LM	25	16.00	22.00	17.8000	1.65831

Table 2. Odontometry measured by the CBCT method

Tabela 2. Odontometrija izmerena metodom kompjuterizovane tomografije konusnog zraka (CBCT)

Root Koren	N	Minimum Minimum	Maximum Maksimum	Average value Srednja vrednost	Standard deviation Standardna devijacija
BM	49	13.80	21.20	17.9137	1.82871
BD	24	15.80	21.80	18.1042	1.66145
P	24	17.80	23.70	20.8958	1.79183
D	25	17.00	23.50	20.5160	1.81284
LM	25	15.70	21.20	17.9500	1.48111

For single-rooted teeth, measurements of root canal length using apex locator and CBCT are shown in s 4-6. Based on the results of the Mann-Whitney U test, it was concluded that there was no statistically significant difference $p > 0.05$ in the measured root length between the two methods in single-rooted teeth.

Table 3. Comparison of apex locator odontometry and CBCT method in multi-rooted teeth

Tabela 3. Poređenje odontometrije apeksnim lokatorom i metodom kompjuterizovane tomografije konusnog zraka (CBCT) kod višekorenih zuba

Root Koren	Measurement_Method Metoda merenja	N	Average value Srednja vrednost	p
BM	MEASUREMENT WITH APEX LOCATOR MERENJE APEKSNIM LOKATOROM	49	48.64	0.767
	CBCT MEASUREMENT CBCT MERENJE	49	50.36	
	Total Ukupno	98		
BD	MEASUREMENT WITH APEX LOCATOR MERENJE APEKSNIM LOKATOROM	24	24.90	0.849
	CBCT MEASUREMENT CBCT MERENJE	24	24.10	
	Total Ukupno	48		
P	MEASUREMENT WITH APEX LOCATOR MERENJE APEKSNIM LOKATOROM	24	24.04	0.826
	CBCT MEASUREMENT CBCT MERENJE	24	24.96	
	Total Ukupno	48		
D	MEASUREMENT WITH APEX LOCATOR MERENJE APEKSNIM LOKATOROM	25	25.42	0.973
	CBCT MEASUREMENT CBCT MERENJE	25	25.58	
	Total Ukupno	50		
LM	MEASUREMENT WITH APEX LOCATOR MERENJE APEKSNIM LOKATOROM	25	23.28	0.284
	CBCT MEASUREMENT CBCT MERENJE	25	27.72	
	Total Ukupno	50		

Table 4. Odontometry with apex locator

Tabela 4. Odontometrija apeksnim lokatorom

	N	Minimum Minimum	Maximum Maksimum	Average value Srednja vrednost	Standard deviation Standardna devijacija
Root canal length Dužina kanala korena	49	13.07	21.07	17.0812	1.74013

Table 5. Odontometry using the CBCT method

Tabela 5. Odontometrija metodom kompjuterizovane tomografije konusnog zraka (CBCT)

	N	Minimum Minimum	Maximum Maksimum	Average value Srednja vrednost	Standard deviation Standardna devijacija
Root canal length Dužina kanala korena	49	14.00	22.00	17.6735	1.77233

The mean value of the absolute difference between the CBCT measurement and the apex locator measurement was the smallest in the group of linguomesial canals and was 0.284 mm, and the largest in the group of distal canals of the lower molars was 1.939 mm. Based on the results of the Mann-Whitney U test, it was concluded that there was no statistically significant difference $p > 0.05$ in the measured length of root canals between the two methods in all groups of roots of multi-rooted teeth as well as in the group of single-rooted teeth.

Table 6. Comparison of odontometry with apex locator and CBCT method
Tabela 6. Poređenje odontometrije apeksnim lokatorom i metodom kompjuterizovane tomografije konusnog zraka (CBCT)

	Measurement Method Metoda merenja	N	Average value Srednja vrednost	p
Root canal length Dužina kanala korena	MEASUREMENT WITH APEX LOCATOR MERENJE APEKSNIM LOKATOROM	49	50.66	0.685
	CBCT MEASUREMENT CBCT MERENJE	49	48.34	
	Total Ukupno	98	100	

DISCUSSION

By applying CBCT, endodontics gets a new diagnostic tool in different stages of endodontic therapy. Odontometry is one of the phases of the endodontic protocol, which determines the working length at which the chemomechanical instrumentation of the root canal is performed. Apex locators are successfully used for odontometry, however, the presence of serous, purulent or hemorrhagic fluid in the canal can interfere with the measurement and give wrong results. On the other hand, in patients who have an implanted pacemaker, the use of an apex locator is contraindicated. Recently, CBCT has been described as new endodontic tool for measuring the length of the root canal [16].

This innovative digital method showed that there is a high correlation between the image of the histological sections of the teeth and the analog CBCT image. The analysis of the results of our research showed that CBCT odontometry requires segmentation of the endodontic space and gives very precise measurements that have small deviations compared to apex locator measurements. In the group of single-rooted teeth, this deviation has no statistical significance ($p = 0.685$). The smallest length measured by the apex locator was 13.07 mm, while the smallest length measured by CBCT was 14 mm. By segmenting the CBCT image, we separated the endodontium from the surrounding tissue - dentin and tooth root cementum [17]. Initial reference points were marked on the incisal edge for anterior teeth and on the top of the vestibular cusp for posterior teeth. The final reference point in both groups was the physiological apical foramen 0.5 mm from the anatomical foramen.

In our study, neither in the group of single-rooted nor in the group of multi-rooted teeth, there was a statistically significant difference between measuring the working length by apex locator and CBCT imaging and that is in agreement with numerous studies [17, 18, 19]. However, there are studies that suggest that CBCT odontometry is an unreliable method for determining working length [20].

Considering that there are larger number of studies with results that indicate reliability of using CBCT for endodontics, the reasons for the opposite findings could be misinterpretation of the results. In the interpretation of the radiographic image, a significant difference was observed between different observers. For this reason, the results of this research were interpreted by a radiology engineer.

In support that CBCT odontometry is a very new and precise method of determining the working length are also the results of our study in which wax models with extracted teeth were used to perform odontometry manually. Access cavities were prepared on the extracted teeth, after which expanders number 08, 10 and 15 were introduced into the canal until the tip of the expander appeared at the anatomical apical foramen. The working length was measured from the stopper positioned on the incisal edge of anterior teeth or on the top of the cusps of lateral teeth, while the second reference point was the anatomical apical foramen. Using the same

positions of the reference points, the measurements were repeated by CBCT. The results showed that deviations of CBCT measurements from manual measurements were less than 1 mm, which had no significant difference [10].

Determination of the working length by CBCT imaging and the ability to manually adjust the path of the line drawn from reference point 1 to reference point 2 is one of the most creative features of Romexis software. This reduces the possibility of error to a minimum. In addition to the length, the therapist gets an insight into the path of the canal system of the root [21, 22].

Current study aimed to correlate the quality of an objective CBCT image with the relatively simple task of estimating the length of a tooth's root canal with an apex locator. The length was scaled in intervals and very suitable for statistical analysis, which confirmed the assumption that the CBCT method is a highly accurate method for determining root canal length. The only ethical obstacle for indicating CBCT odontometry is the amount of radiation. A key principle in radiation protection refers to the optimization of exposure in terms of the well-known principle "as low as reasonably possible" (ALARA). Therefore, knowing what quality is sufficient for a specific diagnostic or treatment task is essential for adopting this principle of radiation protection [23, 24].

REFERENCES

1. Paterson A, Franco V, Patel S, Foschi F. Use of preoperative cone-beam computed tomography to aid in establishment of endodontic working length: A systematic review and meta-analysis. *Imaging Sci Dent.* 2020;50(3):183–92. [DOI: 10.5624/isd.2020.50.3.183] [PMID: 33005575]
2. Decurcio DA, Bueno MR, Silva JA, Loureiro MAZ, Damião Sousa-Neto M, Estrela C. Digital planning on guided endodontics technology, *Braz Dent J.* 2021;32(5):23–33. [DOI: 10.1590/0103-6440202104740] [PMID: 34877975]
3. Moazzy I, Almansour, Saad M, Al-Zubaidi, Abdulmjeed S, Enizy and Ahmed A. Madfa: Comprehensive evaluation of root and root canal morphology of mandibular second molars in a Saudi subpopulation evaluated by cone-beam computed tomography. *BMC Oral Health.* 2022;22(1):267. [DOI: 10.1186/s12903-022-02305-z] [PMID: 35778729]
4. Van Gorp G, Lambrechts M, Jacobs R, Declerck D. Does clinical experience with dental traumatology impact 2D and 3D radiodiagnostic performance in paediatric dentists? An exploratory study. *BMC Oral Health.* 2022;22(1):245. [DOI: 10.1186/s12903-022-02281-4] [PMID: 35725397]

5. Sisli S, Gülen O. Root canal length measurement of molar teeth using cone-beam computed tomography (CBCT): comparison of two-dimensional versus three-dimensional methods. *Eur Oral Res.* 2021;55(2):94–8. [DOI: 10.26650/eor.20210124] [PMID: 34250476]
6. Mahmoud O, Awad Abdelmagied MH, Dandashi AH, Jasim BN, Tawfik Kayali HA, Al Shehadat S. Comparative Evaluation of Accuracy of Different Apex Locators: Propex IQ, Raypex 6, Root ZX, and Apex ID with CBCT and Periapical Radiograph–In Vitro Study. *Int J Dent.* 2021;2021:5563426. [DOI: 10.1155/2021/5563426] [PMID: 34054960]
7. Lo Giudice R, Nicita F, Puleio F, Alibrandi A, Cervino G, Lizio AS, et al. Accuracy of Periapical Radiography and CBCT in Endodontic Evaluation. *Int J Dent.* 2018;2018:2514243. [DOI: 10.1155/2018/2514243] [PMID: 30410540]
8. Kofler B, Jenetten L, Runge A, Degenhart G, Fischer N, Hörmann R, et al. ALADA Dose Optimization in the Computed Tomography of the Temporal Bone: The Diagnostic Potential of Different Low-Dose CT Protocols. *Diagnostics.* 2021;11(10):1894. [DOI: 10.3390/diagnostics11101894] [PMID: 34679601]
9. Lucena C, López JM, Martín JA, Robles V, González-Rodríguez MP. Accuracy of working length measurement: electronic apex locator versus cone-beam computed tomography. *Int Endod J.* 2014;47(3):246–56. [DOI: 10.1111/iej.12140] [PMID: 23772839]
10. Đeri A, Radman-Kuzmanović I, Čavić M, Vujaković I, Arbutina A, Uzelac T, et al. Root canal working length determination using Cone-Beam Computed Tomography. *Stom Glas S.* 2019;66(2):57–65. [DOI: 10.2478/sdj-2019-0006]
11. Đeri A, Brestovac N, Subotić S, Radman Kuzmanović I, Arbutina A, Marin S. CBCT analysis of apical distance between second lower-premolars, first and second lower molars and mandibular canal. *Stom Glas S.* 2021;68(3):122–7. [DOI: 10.2298/SGS2103122D]
12. Marin S, Đeri A, Vidović H, Trtić N, Arbutina A, Pavlič V. Cone-beam computed tomography assessment of the buccal bone thickness in anterior maxillary and mandibular teeth. *Med Pregl.* 2021;74(11–12):362–7. [DOI: 10.2298/MPNS2112362M]
13. Jafarzadeh H, Beyrami M, Forghani M. Evaluation of Conventional Radiography and an Electronic Apex Locator in Determining the Working Length in C-shaped Canals. *Iran Endod J.* 2017;12(1):60–3. [DOI: 10.22037/iej.2017.12] [PMID: 28179926]
14. Shibin J, Prathima GS, Suganya M, Nandhakumar S, Sanguida A, Kavitha M. Evaluation of the working length determination accuracy by cone-beam computed tomography in primary teeth. *Int J Clin Pediatr Dent.* 2022;15(Suppl 1):S92–S96. [DOI: 10.5005/jp-journals-10005-2330] [PMID: 35645504]
15. Wolf TG, Fischer F, Schulze R KW. Correlation of objective image quality and working length measurements in different CBCT machines: An ex vivo study. *Sci Rep.* 2020;10(1):194. [DOI: 10.1038/s41598-020-76424-4] [PMID: 33173072]
16. Jeger FB, Janner SF, Bornstein MM, Lussi A. Endodontic working length measurement with preexisting cone-beam computed tomography scanning: a prospective, controlled clinical study. *J Endod.* 2012;38(7):884–8. [DOI: 10.1016/j.joen.2012.03.024] [PMID: 22703648]
17. Connert T, Hülber-J M, Godt A, Löst C, ElAyouti A. Accuracy of endodontic working length determination using cone beam computed tomography. *Int Endod J.* 2014;47(7):698–703. [DOI: 10.1111/iej.12206] [PMID: 24134733]
18. Yılmaz F, Kamburoğlu K, Şenel B. Endodontic Working Length Measurement Using Cone-beam Computed Tomographic Images Obtained at Different Voxel Sizes and Field of Views, Periapical Radiography, and Apex Locator: A Comparative Ex Vivo Study. *J Endod.* 2017;43(1):152–6. [DOI: 10.1016/j.joen.2016.09.019] [PMID: 27986097]
19. Faraj BM. Preoperative Estimation of Endodontic Working Length with Cone-Beam Computed Tomography and Standardized Paralleling Technique in comparison to Its Real Length. *Bio-med Res Int.* 2020;2020:7890127. [DOI: 10.1155/2020/7890127] [PMID: 33102594]
20. Lucena C, López JM, Martín JA, Robles V, González-Rodríguez MP. Accuracy of working length measurement: electronic apex locator versus cone-beam computed tomography. *Int Endod J.* 2014;47(3):246–56. [DOI: 10.1111/iej.12140] [PMID: 23772839]
21. Hilgenfeld T, Juerchott A, Deisenhofer UK, Weber D, Rues S, Rammelsberg P, et al. In vivo accuracy of tooth surface reconstruction based on CBCT and dental MRI-A clinical pilot study. *Clin Oral Implants Res.* 2019;30(9):920–7. [DOI: 10.1111/clr.13498] [PMID: 31257638]
22. Janner SF, Jeger FB, Lussi A, Bornstein MM. Precision of endodontic working length measurements: a pilot investigation comparing cone-beam computed tomography scanning with standard measurement techniques. *J Endod.* 2011;37(8):1046–51. [DOI: 10.1016/j.joen.2011.05.005] [PMID: 21763892]
23. Paterson A, Franco V, Patel S, Foschi F. Use of preoperative cone-beam computed tomography to aid in establishment of endodontic working length: A systematic review and meta-analysis. *Imaging Sci Dent.* 2020;50(3):183–92. [DOI: 10.5624/isd.2020.50.3.183] [PMID: 33005575]
24. Zidan M, Schwindling FS, Juerchott A, Mente J, Gehrig H, Nitka M, et al. Endodontic working length measurements of premolars and molars in high-resolution dental MRI: a clinical pilot study for assessment of reliability and accuracy. *Clin Oral Investig.* 2022;26(11):6765–72. [DOI: 10.1007/s00784-022-04636-1] [PMID: 35861757]

Received: 5.10.2023 • Accepted: 15.12.2023

Uporedna analiza određivanja dužine kanala korena zuba pomoću kompjuterizovane konusne tomografije i apeksnog lokatora

Aleksandra Đeri¹, Irena Radman Kuzmanović¹, Adriana Arbutina², Renata Josipović¹, Saša Marin³, Mirjana Umićević-Davidović²

¹Univerzitet u Banjoj Luci, Medicinski fakultet, Katedra za bolesti zuba, Banja Luka, Republika Srpska;

²Univerzitet u Banjoj Luci, Medicinski fakultet, Katedra za ortodontiju, Banja Luka, Republika Srpska;

³Univerzitet u Banjoj Luci, Medicinski fakultet, Katedra za oralnu hirurgiju, Banja Luka, Republika Srpska

KRATAK SADRŽAJ

Uvod Određivanje dužine kanala korena zuba je jedan od ključnih faktora koji mogu uticati na ishod endodontske terapije. Pogrešno određena radna dužina rezultira nedovoljno napunjenim kanalom ili prepunjenim kanalom.

Cilj ovog rada je bio da se proveri efikasnost primene kompjuterizovane konusne tomografije (CBCT) i apeksnog lokatora u određivanju radne dužine kanala korena zuba.

Materijal i metode Endodontska procedura je sprovedena po endodontskom protokolu *lege artis* na 98 zuba. Zub su podeljeni u grupe jednokorenih i višekorenih zuba. U obe grupe radna dužina je izmerena apeksnim lokatorom (Woodpex III) i CBCT merenjem (Planmeca Viso). Kod višekorenih zuba kanali su prema morfološkom položaju svrstani u sledeće grupe: lingvomezijalni (LM), bukomezijalni (BM), bukodistalni (BD), palatinalni (P) i distalni (D) kanali. Odontometrija apeksnim lokatorom je vršena na licu mesta od strane operatera Univerzitet u Banjaluci, a CBCT analiza je vršena od strane inženjera radiologije u radiološkom centru 3DENT u Banjaluci.

Rezultati CBCT odontometrija je imala mala odstupanja od odontometrije apeksnim lokatorom. Srednja vrednost apsolutne razlike između CBCT merenja i merenja apeksnim lokatorom bila je najmanja u grupi lingvomezijalnih kanala i iznosila je 0,284 mm, a najveća u grupi distalnih kanala donjih molara – 1,939 mm. Na osnovu rezultata Man–Vitnijevog U testa došlo se do zaključka da nije postojala statistički značajna razlika ($p > 0,05$) u izmerenoj dužini kanala korena zuba između dve metode kod svih grupa korenova višekorenih zuba, kao ni u grupi jednokorenih zuba.

Zaključak CBCT odontometrija je jednako pouzdana kao i odontometrija apeksnim lokatorom.

Ključne reči: dužina kanala korena zuba; CBCT dijagnostika u stomatologiji; odontometrija

UVOD

Današnja stomatološka procedura neizostavno uključuje upotrebu digitalizovanih stomatoloških aparata. Za digitalizovano određivanje dužine kanala korena zuba može da se koristi konusna dentalna tomografija (cone beam conus tomography – CBCT). U CBCT odontometriji pacijent se izlaže minimalnom nivou rendgenskog zračenja dok se vrši skeniranje unutrašnjosti kanala korena zuba, endodonticijuma. CBCT uređaj emituje konusno rendgensko zračenje, a detektori prikupljaju informacije o načinu prolaska RTG zraka kroz zubne i okolne strukture. Nakon skeniranja, prikupljeni podaci se koriste za rekonstrukciju trodimenzionalne slike zubnih struktura [1, 2]. Softver za obradu slike omogućava endodontima da izvrše precizna merenja dužine kanala korena zuba. Međutim, zbog izloženosti pacijenta rendgenskom zračenju, upotreba CBCT-a se obavlja s oprezom i u skladu sa strogo kontrolisanim kliničkim indikacijama, pogotovo kada se endodontski protokol sprovodi kod dece [3, 4, 5].

Odluka o korišćenju CBCT-a u stomatološkom tretmanu obično se donosi na osnovu potreba za preciznim dijagnostičkim informacijama i planiranjem tretmana. Iako su odontometrijski aparati, poznati i kao apeksni lokatori, korisni u određivanju tačne dužine korena zuba tokom endodontskih tretmana, postoji nekoliko mogućih nedostataka ili izazova koji se mogu javiti pri njihovoj upotrebi [6].

Apeksni lokatori se baziraju na električnoj impedanci ili zvučnim signalima kako bi odredili dužinu kanala korena zuba.

Međutim, različiti faktori, kao što su prisustvo tečnosti ili krvarenje u kanalu, prisustvo metalnih ispuna ili zakrivljen kanal korena, mogu dovesti do netačnih rezultata. To može dovesti do suboptimalnog lečenja, uključujući prekomerno ili nedovoljno čišćenje i preparaciju kanala [7, 8]. Tačna upotreba apeksnog lokatora zahteva veštog operatera. Pogrešno postavljanje ili korišćenje aparata može rezultirati netačnim merenjima. Apeksni lokatori se ne preporučuju u određenim situacijama, kao što je prisustvo metalnih krunica ili kad pacijent ima ugrađen pejsmejker, te bi upotreba niskofrekventne stuje mogla poremetiti ritam pejsmejкера. Takođe treba voditi računa o blizini mandibularnog kanala kod endodontskog protokola na donjim bočnim zubima jer neadekvatna odontometrija može dovesti do povrede mandibularnog kanala ukoliko je u neposrednoj blizini foramena apikale. U takvim slučajevima je preporuka da se koristi CBCT odontometrija kao alternativna metoda [9–12].

Apeksni lokatori zahtevaju održavanje i kalibraciju kako bi bili tačni. Neodgovarajuće održavanje ili kvarovi u aparatu mogu dovesti do netačnih merenja. Zatim, kvalitetni apeksni lokatori mogu predstavljati investiciju za stomatološku praksu. S druge strane, apeksni lokatori obično nisu izvor jonizirajućeg zračenja kao rendgenski aparati, ali koriste električne signale ili zvučne talase. Ipak, pitanje izloženosti pacijenta elektromagnetnom zračenju ostaje tema zabrinutosti i istraživanja. Iz navedenog se uočava potreba za novom, savremenijom metodom odontometrije. Cilj ovog rada bio je da ispita pouzdanost digitalizovanog merenja dužine kanala korena zuba pomoću CBCT odontometrije [13, 15].

MATERIJAL I METODE

Istraživanje je sprovedeno u okviru projekta Medicinskog fakulteta Univerziteta u Banjaluci na Odseku dentalne medicine pod pokroviteljstvom Ministarstva za nauku, tehnološki razvoj i informacione sisteme Vlade Republike Srpske (br. projekta 19/6-020/961-48/18) kao retrospektivna studija u periodu 2019–2022. godine. U istraživanje je uključeno 196 kanala korenova zuba koji su bili indikovani za endodontsku terapiju. Na kompletnom uzorku su izmerene dužine kanala korena zuba – odontometrija metodom CBCT (Planmeca ProMax 3D Classic (Planmeca, Finland) sa veličinom voksela od 0,2 mm i vidnog polja 4 × 4 cm) i određene dužine kanala korena zuba apeksnim lokatorom Woodpex III (Woodpecker Medical Instrument Co, Guilin, China).

Formirano je šest grupa za merenje odontometrije:

1. grupa: Palatinalni kanali gornjih višekorenih zuba – 24
2. grupa: Bukomezijalni kanali gornjih i donjih višekorenih zuba – 49
3. grupa: Bukodistalni kanali gornjih višekorenih zuba – 24
4. grupa: Lingvomezijalni kanali donjih višekorenih zuba – 25
5. grupa: Distalni kanali donjih višekorenih zuba – 25
6. grupa: Kanali jednokorenih zuba gornje i donje vilice – 49

1. CBCT odontometrija

Analizom CBCT preseka prvo smo utvrdili poziciju anatomskog foramena apikale, koji predstavlja prvu referentnu tačku. Potom su vršena linijska merenja do druge referentne tačke (određene proizvoljno – incizalna ivica, vrh kvržice ili zakrivljena površina) (Slika 1). Linijska merenja su paralelna sa aksijalnom osovinom zuba i vrše se od jedne do druge referentne tačke, pri čemu treba izabrati onaj aksijalni presek koji omogućava povlačenje ravne linije od anatomskog foramena do vrha kvržice ili incizalne ivice zuba. Merenje je pouzdanije ukoliko se izvrši i na meziodistalnim i na vestibulooralnim presecima, nakon čega se izračunava srednja vrednost merenja i uzima kao radna dužina. Kod zakrivljenih kanala se predlaže korišćenje segmentiranih linijskih merenja koja međusobno čine određeni ugao. Nedostatak ovakve metode odontometrijskog merenja je taj da se referentne tačke za merenje postavljaju prema zakrivljenoj putanji kanala, što može da utiče na ponovljivost merenja. 3D Endo-software (Planmeca Viso, Helsinki, Finland) ima inovativnu osobinu da detektuje poluautomatsku putanju kanala korena zuba, nakon skeniranja ulaza u kanal, tako da se minimizira mogućnost subjektivne greške operatera. Softver takođe kompenzuje zakrivljene površine i neravnine ili udubljenja u unutrašnjosti kanala, što daje pouzdaniju izmerenu veličinu (Slika 2).

2. Odontometrija apeksnim lokatorom

Elektronsko određivanje radne dužine korišćenjem apeksnog lokatora je bazirano na činjenici da je otpor između vrha endodontskog instrumenta koji je u kontaktu sa parodontom i oralne mukoze otprilike konstantan i iznosi 6.5 kΩ. Meka tkiva

su provodnici niskofrekventne naizmjenične struje, tako da se kontaktom endodontskog instrumenta sa parodontalnim tkivom zatvara strujni krug, što se očitava na displeju apeksnog lokatora. U trenutku kada je na displeju uočeno da se nalazimo u području foramena apikale (prva referentna tačka), gumeni graničnik se postavlja u poziciju koja određuje drugu referentnu tačku. Nakon toga se endodontski instrument uklanja iz kanala i meri se distanca između prve i druge referentne tačke. Dobijena vrednost je radna dužina kanala korena zuba (Slika 3).

REZULTATI

Kod višekorenih zuba (molarna regija) merenja su prikazana pojedinačno za bukomezijalni (BN), lingvomezijalni (LM), palatinalni (P) i distalni (D) kanal. Na osnovu rezultata Man-Vitnijevog U testa došlo se do zaključka da nije postojala statistički značajna razlika ($p > 0,05$) u izmerenoj dužini kanala korena zuba između dve metode kod svih grupa višekorenih zuba i u izmerenoj dužini korena između dve metode kod jednokorenih zuba.

Srednja vrednost apsolutne razlike između CBCT merenja i merenja apeksnim lokatorom bila je najmanja u grupi lingvomezijalnih kanala i iznosila je 0,284 mm, a najveća u grupi distalnih kanala donjih molara – 1,939 mm. Na osnovu rezultata Man-Vitnijevog U testa došlo se do zaključka da nije postojala statistički značajna razlika ($p > 0,05$) u izmerenoj dužini kanala korena zuba između dve metode kod svih grupa korenova višekorenih zuba, kao ni u grupi jednokorenih zuba.

DISKUSIJA

Primenom dentalnog CT-a endodoncija dobija novo dijagnostičko sredstvo u različitim fazama endodontske terapije. Odontometrija je jedna od faza endodontskog protokola kojom se određuje radna dužina na kojoj se vrši mehaničko-medikamentozna obrada kanala korena zuba. Apeksni lokatori se uspešno koriste za odontometriju, međutim prisustvo serozne, gnojne ili hemoragijske tečnosti u kanalu može da ometa merenje i daje pogrešne rezultate. S druge strane, kod pacijenata koji imaju ugrađen pejsmejker, kontraindikovana je upotreba apeksnog lokatora. Nedavno je CBCT opisan kao zanimljiv endodontski alat za merenje dužine kanala korena zuba, tj. određivanje odontometrije [16].

Ova inovativna digitalna metoda je pokazala da postoji visoka korelacija između slike histoloških preseka zuba i analognih CBCT slike. Analiza rezultata ovog istraživanja je pokazala da CBCT odontometrija zahteva segmentaciju endodontskog prostora i daje veoma precizna merenja, koja imaju mala odstupanja u odnosu na merenja apeksnim lokatorom. U grupi jednokorenih zuba to odstupanje nema statističku značajnost ($p = 0,685$). Najmanja izmerena dužina apeksnim lokatorom je 13,07 mm, dok je najmanja izmerena dužina CBCT snimanjem 14 mm. Segmentacijom CBCT slike odvajamo endodoncijum od okolnog tkiva-dentina i cementa korena zuba [17]. Početne referentne tačke su markirane na incizalnoj ivici kod frontalnih zuba i na vrhu vestibularne kvržice kod bočnih zuba. Završna referentna tačka u obe grupe bio je fiziološki foramen apikale 0,5 mm od anatomskog foramena.

U našoj studiji ni u grupi jednokorenih ni u grupi višekorenih zuba nema statistički značajne razlike između merenja radne dužine apeksnim lokatorom i CBCT snimanjem, što je u saglasnosti sa brojnim studijama [17, 18, 19]. Ipak, postoje studije koje su eksplicitne u tvrdnji da je CBCT odontometrija nepouzdan metod određivanja radne dužine [20].

S obzirom na to da je mnogo veći broj studija sa rezultatima koji ukazuju na pouzdanost korišćenja CBCT za endodonciju, za suprotne nalaze treba tražiti razloge u pogrešnoj interpretaciji rezultata. U interpretaciji radiografske slike primećena je značajna zavisnost između tačnosti kod različitih posmatrača. Iz tog razloga rezultati ovog istraživanja interpretirani su od strane jednog inženjera radiologije.

U prilog potvrdi da je CBCT odontometrija veoma pouzdan i precizan metod određivanja radne dužine ukazuju i rezultati naše studije, u kojoj su korišćeni voštani modeli sa ekstrahovanim zubima na kojima je odontometrija urađena ručno. Na ekstrahovanim zubima su preparisani pristupni kaviteti, nakon čega su proširivači broj 08, 10 i 15 uvođeni u kanal do pojave vrha proširivača na anatomskom foramenu apikale. Radna dužina je merena od „stopera“ pozicioniranog na incizalnoj ivici frontalnih zuba ili na vrhu kvržice bočnih zuba, dok je druga referentna

tačka anatomski foramen apikale. Koristeći iste pozicije referentnih tačaka, merenja su ponovljena CBCT snimanjem. Rezultati su pokazali da su odstupanja CBCT merenja od ručnog merenja manja od 1 mm, što apsolutno nema klinički značaj [10].

Određivanje radne dužine CBCT snimanjem i mogućnost ručnog podešavanja putanje linije koja se povlači od referentne tačke 1 do referentne tačke 2 jedna je od najkreativnijih karakteristika softvera Romexis. Time se mogućnost greške svodi na minimum. Pored radne dužine, terapeut dobija uvid u putanju kanalnog sistema pulpe korena [21, 22].

Ovo istraživanje je imalo za cilj da poveže kvalitet objektivne CBCT slike sa relativno jednostavnim zadatkom procene dužine kanala korena zuba apeksnim lokatorom. Dužina je skalirana u intervalima i veoma pogodna za statističku analizu, koja je potvrdila pretpostavku da je CBCT metoda visoko precizna metoda za određivanje odontometrije. Jedina etička prepreka za indikovanje CBCT odontometrije je količina zračenja. Ključni princip u zaštiti od zračenja odnosi se na optimizaciju izloženosti u smislu dobro poznatog principa „nisko koliko je razumno moguće“ (ALARA). Dakle, saznanje koji je kvalitet dovoljan za određeni dijagnostički ili tretmanski zadatak je od suštinskog značaja za usvajanje ovog principa zaštite od zračenja [23, 24].